

Active contractions of the cervix in the latent phase of labour

Drago Rudel *Clinical Research Consultant*, Marjan Pajntar *Head of Department Research Unit, Department of Obstetrics and Gynaecology, Medical Centre Ljubljana, Slovenia*

- Objective** To study the activity of the human uterine cervix at the onset of labour and further characterise cervical asynchronous electromyographic (EMG) activity in the latent phase.
- Design** Prospective observational study. Setting Clinical hospital in Ljubljana.
- Participants** Forty-seven healthy nulliparous women with relatively unripe cervixes requiring induction of labour.
- Methods** Simultaneous registration of a cervical EMG and of the intrauterine pressure at the very early stage of labour; subsequent EMG signal processing to determine its time, amplitude and frequency parameters.
- Main outcome measures** Simultaneous comparison of the cervical EMG and the mechanical activity of the uterine corpus to deduce electrical properties of the cervical smooth muscle tissue and its activity.
- Results** EMG bursts, asynchronous with the contractions of the uterine corpus, were registered in 20 out of 47 women. In 14 women bursts appeared independent of uterine corpus contractions and in six they followed the peak of contractions. The bursts had low average median frequency (0.3 Hz). In seven women bursts were superimposed onto a background EMG (median frequency = 1.2 Hz).
- Conclusions** Bursts in the cervical EMG may appear asynchronously with the uterine contractions. Bursts not related to contractions suggest active and independent cervical muscle activity. The bursts which follow contractions may be an active response of the cervical musculature to passive stretching during a contraction. The EMG frequency content suggests two different contraction mechanisms or a different origin of the EMG in the cervix.

INTRODUCTION

According to recent findings, the cervix should be considered a dynamic muscular structure playing an important role during pregnancy and labour^{1,7}. The smooth muscle fibres present in the cervix⁸⁻¹⁰ can actively contract during pregnancy¹¹ and labour^{6,12}. In the latent phase of labour the cervix may contract rather than dilate in response to uterine corpus myometrial activity⁶. The latter may have clinical implications for the management of the early stage of labour^{5,13-15}. A better understanding of the role of smooth muscle in the cervix at term is required if clinicians wish to influence the process of cervical ripening and dilatation. This is particularly true for the management of induced labour in women with an unripe cervix.

The electromyographic (EMG) signal, recorded from the cervix, is believed to reflect actual activity of cervical smooth muscle cells.^{1,6,12,16-19} EMG activity can be independent of myometrial contractions of the

uterine corpus, or related to them^{12,19-21}. Independent activity of the smooth muscle characterises the latent phase of labour^{6,22,23}. Olah¹⁹ registered the EMG activity in the cervix which exhibited active cervical contractions in the latent phase of labour, and which differed from the activity registered when the cervix dilated only passively with uterine myometrial contractions.

It has already been proven that in uterine corpus smooth muscle, EMG bursts preceded uterine corpus mechanical activity. Actually, they appear synchronously with contractions²⁴⁻²⁸. Analysing EMG records derived from the cervical muscular tissue in relatively unripe cervixes during the early latent phase of induced labour, we noticed that bursts in the cervical EMG signal also appear asynchronously with uterine contractions. The aim of this study was to characterise this asynchronous EMG activity and relate it to uterine contractions. It was suspected that the activity represented an independent smooth muscle activity of the cervix originating in the cervix.

10. Grammatopoulos D, Milton NGN, Hillhouse EW. The human myometrial CRF receptor: G proteins and second messengers. *Mol Cell Endocrinol* 1994; 99: 245-250.
11. Ferre F, De Pariente D, Breuiller M, Cedard L. Inhibition of human myometrial cyclic AMP phosphodiesterase by uterine relaxant drugs. *Biochem Pharmacol* 1978; 27: 1292-1294.
12. Quartero HWP, Srivatsa G, Gillham B. Role for cyclic adenosine monophosphate in the synergistic interaction between oxytocin and corticotrophin-releasing factor in isolated human gestational myometrium. *Clint Endocrinol* 1992; 36: 141-145.
13. Kawarabayashi T, Kishikawa T, Sugimori H. Effects of ex tem al calcium, magnesium and temperature on spontaneous contractions of pregnant human myometrium. *Biol Reprod* 1989; 40: 942-948.
14. Kinsler VA, Thornton S, Ashford MU, Melin P, Smith SK. The effect of the oxytocin antagonists F314 and F792 on the in vitro contractility of human myometrium. *Br J Obstet Gynaecol* 1996; 103: 373-375.
15. Jones GD, Poston L. The role of endogenous nitric oxide synthesis in contractility of term or preterm human myometrium. *Br J Obstet Gynaecol* 1997; 104: 241-245.
16. Hillhouse EW, Grammatopoulos D, Milton NGN, Quartero HWP. The identification of a human myometrial corticotrophin releasing hormone receptor which increases its affinity during pregnancy. *J Clin Endocrinol Metab* 1993; 76: 736-741.
17. Chen R, Lewis KA, Perrin MH, Vale VW. Expression cloning of a human corticotrophin releasing factor. *Proc Natl Acad Sci USA* 1993; 90: 8967-8971.
18. Vita N, Laurent P, Lefort S et al. Primary structure and functional expression of mouse pituitary and human brain corticotrophin releasing factor receptor. *FEBS Lett* 1993; 335: 1-5.
19. Liaw CW, Lovenberg TW, Barry G, Oltersdorf T, Grigoriadis DE, De Souza EB. Cloning and characterization of the human corticotrophin releasing factor-2 receptor complementary deoxyribonucleic acid. *Endocrinol* 1996; 137: 72-77.
20. Rodriguez-Linares B, Linton EA, Phaneuf S. Expression of corticotrophin releasing hormone receptor mRNA and protein in the human myometrium. *J Endocrinol* 1998; 156: 15-21.
21. Rodriguez-Linares B, Phaneuf S, Lopez Bernal A, Linton EA. Levels of corticotrophin releasing hormone receptor subtype 1 mRNA during labour in human myometrium measured by competitive PCR. *J Soc Gynecol Obstet* 1998; 5 (Suppl): 185 A.
22. Ferre F, Germain G, Leroy MJ, Breuiller M. Relationship between myometrial phosphodiesterase (PDE) activity and the RNA/DNA ratio at various stages of gestation in primates. *Acta Physiol Hungarica* 1985; 65: 433-441.
23. Europe-Finner GN, Phaneuf S, Watson SP, Lopez Bernal A. Identification and expression of G-proteins in human myometrium: Upregulation of G₁₂ in pregnancy. *Endocrinol* 1993; 132: 2484-2490.
24. Europe-Finner GN, Phaneuf S, Tolkovsky AM, Watson SP, Lopez Bernal A. Down-regulation of G₁₂ in human pregnancy in term and preterm labor: A mechanism for parturition. *J Clin Endocrinol Metab* 1994; 79: 1835-1839.

METHODS

Forty-seven healthy nulliparous women undergoing induction of labour at term with amniotomy and subsequent oxytocin infusion were enrolled in the study. These cases were selected from among 200 cases in which EMG and IUP were registered electronically. Criteria for selection were:

1. EMG and IUP data registered electronically for at least one hour after amniotomy;
2. No major artefacts in the selected 20 minute interval records;
3. Syntocinon not administered within the selected interval.

Main indications for induction were period of gestation exceeding 40 weeks and milky or meconial amniotic fluid. In most of the 47 women the CTG showed no or infrequent uterine contractions before the onset of labour.

The study was approved by the national medico-ethical committee and informed consent was obtained from each woman before undergoing the measurements.

After admission to the delivery room, cervical ripeness was estimated according to the Bishop score ~9 (mean 5.6, SD 1.99), and an amniotomy was performed. Intrauterine pressure (IUP) was measured by a fluidfilled open-end intra-amniotic catheter inserted into the uterine cavity and a pressure probe (Hewlett Packard 1286). Prior to each recording, baseline pressure was adjusted to 0 mmHg. IUP was recorded by a cardiotocograph (CTG-HP8030A, Hewlett Packard, San Diego, California, USA). In this study the IUP records were used only as a synchronisation signal for the cervical EMG, giving information on uterine peak contraction and duration. Additionally, an ECG electrode was attached to the infant's head to monitor the fetal heart rate by the CTG. Syntocinon was commenced after the 20 minutes of observation had elapsed in most subjects.

To record the EMG activity of smooth muscle tissue on the exterior wall of the cervix, a pair of fetal spiral steel electrodes (Hewlett Packard 15130A) was applied to the outer aspect of the cervix (proximal part of the portio), circumferential to the cervical canal at 9 o'clock and 12 o'clock. A reference flat metal (Sn) electrode was attached to the woman's thigh. Neither the electrodes themselves nor their application caused any pain or discomfort to the women.

The differential preamplifier and the amplifier with an isolation unit were used to amplify ($A = 2000$) and process the obtained EMG signals. Analogue signals of EMG and a signal corresponding to IUP were registered on the CTG chart recorder. Additionally, the EMG and the IUP were sampled at 20 Hz and the data were written on a personal computer hard disk for subsequent processing. The EMG activity was registered throughout the duration of labour. For the purpose of this study, a 20 minute interval was selected out of each labour record, starting as close to amniotomy as possible. A personal computer with a MathLab software tool (Version 4, MathWorks Inc, Natick, Massachusetts, USA) was used for signal processing, analyses and graphic presentation. IUP and EMG recordings were filtered digitally (Butterworth band pass filter $0.08 \text{ Hz} < \text{EMG} < 4.0 \text{ Hz}$; lowpass second order Butterworth filter $\text{IUP} < 0.03 \text{ Hz}$). In this way the influence of artefacts was also diminished.

EMG and IUP signal records were visually assessed according to the time of appearance of bursts of EMG activity with regard to contractions (peaks in IUP). Additionally, EMG signal recordings were processed in time and frequency domains, respectively. The root mean square (RMS) of the EMG signal voltage (U_{RMS}) and the median frequency of the EMG signal were calculated for each 5 second interval of the 20 minute observation period. The power spectral density (PSD) was also calculated and plotted for the analysis of frequency content of the EMG signal.

RESULTS

Time domain

Visual assessment of EMG and IUP signal records according to the time of appearance of bursts of EMG activity with regard to contractions (peaks in IUP) showed that in 27 (57.4%) women EMG signals contained only bursts synchronous with uterine corpus contractions. In 20 (42.6%) we established that along with synchronous bursts of EMG activity, asynchronous EMG bursts also appeared. Data for cervical ripeness for the women expressing asynchronous EMG bursts are shown in Table 1. Asynchronous bursts appeared either independent ($n = 9$; 19.2%) of a uterine corpus contractions (during the burst no significant increase in IUP was registered), or were delayed to the peak in

Table 1. Average cumulative and some components of the Bishop score²⁹, with standard deviation in parentheses, for the observed groups.

	Group with asynchronous independent bursts (n = 14)	Group with asynchronous delayed bursts (n = 6)	<i>p</i>
Bishop	5.36 (1.95)	6.83 (0.98)	<0.098
Effacement	2.20 (0.96)	2.83 (0.41)	<0.058
Consistency	1.36 (0.74)	1.50 (0.55)	<0.679
Dilatation	1.07 (0.27)	1.77 (0.41)	<0.540

Bishop' is a cumulative score, 'effacement', 'consistency' and 'dilatation' are three of five Bishop score components IUP ($n = 11$; 23-4%). Delayed bursts start at a trailing edge of the IUP curve (the contraction culminates) and last for up to several minutes. Among the 20 women with asynchronous EMG bursts, in seven (35%) EMG bursts were superimposed onto a background EMG activity. The amplitude of the background EMG signal, compared with that at bursts, differed from woman to woman. In some women the background signal amplitude was almost the same value as that of bursts.

In Fig. 1, IUP and EMG signals, together with the calculated variables (U_{RMS} and median frequency) of a representative member of the group also expressing delayed EMG bursts, are presented. Four contractions, registered as an increase in the IUP signal (trace 1), occurred in the observed 20 minute interval.

The EMG signal of the cervix (trace 2) is composed of two components: a permanent high density background activity of low amplitude (approximately $\pm 30 \mu Vp$) and superimposed low density EMG bursts with an amplitude almost three times higher (approximately $\pm 100 \mu Vp$). The EMG signal contains both independent and delayed asynchronous bursts. The first EMG burst is not associated with any contraction as no increase in the IUP signal is observed. The second and the third EMG bursts start at a trailing edge of the IUP curve (contraction), whereas the last burst is synchronous with the corresponding contraction.

EMG signal amplitude values (U_{RMS}) (trace 3) are high in the periods of burst appearance and low for the EMG background activity. Median frequency variable (trace 4) has high value (1.3 Hz) in the absence of EMG bursts. The

median frequency value drops to 0.3 Hz at the time of uterine contractions. U_{RMS} and median frequency almost alternate in the amplitude: when median frequency is high, U_{RMS} is low and *vice versa*.

Frequency domain

The EMG signal frequency spectrum diagrams, the power spectral density charts, presents the frequency content of the EMG signal. For the group with asynchronous bursts, the power spectral density chart consisted of one ($n = 13$), or two ($n = 7$) frequency bands. In all 20 women with asynchronous EMG activity, the low frequency band was present containing frequency components up to 0.6 Hz. The second high frequency band, ranging from 1.0 Hz to 1.3 Hz, was noticed in seven women. The well-expressed EMG bursts with high amplitude, low frequency signals contributed to the low frequency part of the spectrum. The background EMG activity contributed to the second frequency band. Average values of the median frequency of EMG bursts in the 20 minute intervals was 0.30 (0.04 SD) in the group having asynchronous EMG bursts not related to contractions, and 0.29 (0.02 SD) in the group with delayed EMG bursts.

The power spectrum of the EMG signal for the representative case described above has two clearly separated bands as shown in Fig. 2: the lower with frequencies up to 0.6 Hz and the higher ranging from 1.0 Hz to 1.3 Hz. There is a clear gap between these two bands. The median frequency of the lower band is 0.3 Hz and the upper band 1.2 Hz.

DISCUSSION

In early labour the cervical smooth muscle tissue may contract. Its activity is characterised by a pattern of EMG signals derived from the tissue during labour. The detection of EMG signals by spiral electrodes inserted into the outer surface of the cervix enables a closer look into the behaviour of the smooth muscle tissue of the cervix *in vivo*¹².

As the observed 20 minute intervals were taken as close to the onset of each labour as possible, we considered the dilatation process

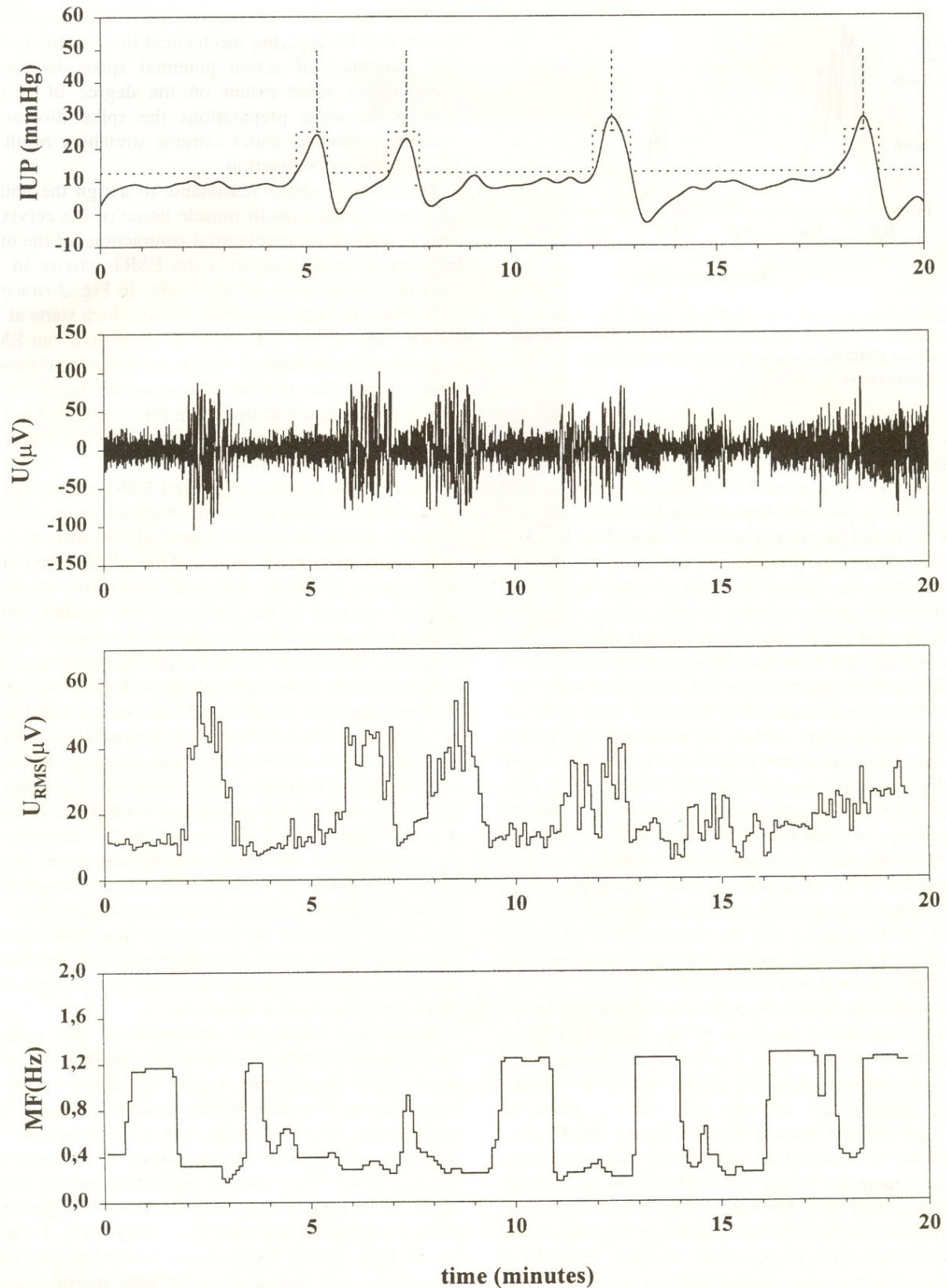
of the cervix during the 20 minute period to have been minimal. It was assumed that the EMG electrodes stayed almost at the same position throughout the observed interval and that the minimal electrode repositioning did not influence the measurements considerably.

All women were nulliparous, admitted for delivery with relatively unripe and most likely pathological cervixes. The average cumulative Bishop score (Table 1) in cases with asynchronous EMG bursts was relatively high, cervixes were almost effaced but rigid and the dilatation scores were low. Although there is a difference in the average Bishop score between the cases expressing independent asynchronous bursts and those also having delayed asynchronous bursts, the differences in cervical ripeness are statistically not significant, probably due to the low number of cases with delayed bursts.

Two types of EMG activity were registered

from the cervix; a permanent background activity and more pronounced bursts superimposed onto it. It is a common opinion that EMG bursts of the uterine smooth muscles are synchronous with myometrial contractions of the uterine corpus^{19,24-27}. Besides synchronous EMG bursts we also found asynchronous bursts in the cervix not associated with the uterine contractions. In the presented case (Fig. 1, trace 2), the first EMG burst appears at the moment when a contraction of the uterine corpus itself is not expressed (no increase in the intrauterine pressure). Asynchronous EMG activity not being associated with uterine contractions could be attributed to the functionally independent muscle activity of the human cervix^{6,12,19,20,30}. Pajntar⁷ states that in an unripe cervix such activity represents prolonged muscular activity, which helps to keep the fetus in the uterus during pregnancy.

ACTIVE CONTRACTIONS OF THE CERVIX DURING LABOUR 449



The next two EMG bursts in trace 2 start at the falling edge of the IUP and are therefore delayed to peak uterine contraction. A possible explanation for their existence could be found in the phenomenon described by Olah and Gee⁶. They reported cases in which the cervix contracted rather than dilated in response to the myometrial activity of the uterine corpus in early labour, when the cervix was uneffaced and < 4 cm dilated. Mechanically registered cervical dilatation during a uterine contraction was followed by negative cervical dilatation-constriction of the cervical canal below the initial level of dilatation. According to the authors, the exhibited constriction was caused by active contractions of the cervical smooth muscles delayed to the peaks of IUP. The temporal analysis of our EMG signals offers a possibility to relate the observations of both research groups and complement the results of Olah¹⁹, although the electrical and mechanical activity of the same phenomenon were registered in two different measurement settings. EMG bursts delayed to IUP peaks suggest that the bursts reflect electrical activity of the cervical smooth muscles during constriction of the cervix as described by Olah¹⁹.

The mechanism underlying the delayed EMG bursts could be the active response of the cervical smooth muscle tissue to stretching. From obstetrical practice it is well known the stretching of the wall of the uterine corpus triggers its activity (e.g. at the point of increased tension caused by the fetus). Kao²⁸ confirmed that in a parturient myometrial tissue specimen electrical activity might be initiated by stretching. Kawarabayashi and Marshall³¹ demonstrated the same phenomenon in the circular muscles of the wall of the uterine corpus in a pregnant rat. Further, it has been confirmed that in some animal and human preparations the stretching of the smooth muscle tissue may elicit the EMG activity.³²⁻³⁻¹ On sample strips taken from pregnant human myometrium Kao²⁸ demonstrated that the EMG activity of the smooth muscle tissue could also be initiated by applying mechanical force to the tissue. The frequency of action potential spike

discharges depended to some extent on the degree of stretch applied. In some preparations the spike discharges became continuous under extreme stretching resulting in a continuous contraction.

Therefore, it seems reasonable to assign the ability described to the smooth muscle tissue of the cervix *in vivo* as well. If so, myometrial contractions of the uterine corpus could also elicit the EMG activity in the smooth muscle tissue of the cervix. In Fig. 2 (trace 2) the second and the third EMG burst, which starts at the falling edge of the IUP, could be considered an EMG response to a mechanical stretch of the cervical muscle tissue during the uterine corpus contractions. If the above assumption was true, then this would be the first documentation of the stretch-elicited EMG activity registered *in vivo* in the human cervix.

The opinion that the registered EMG bursts belong to the EMG activity of the myometrium of the uterine corpus is hardly acceptable, especially because the time delay between each IUP peak and the related EMG burst maximum is too long. It is well known that electrical activity initiated in the fundus of the uterine corpus propagates along the myometrium by means of gap junctions. The activity could therefore be registered as a delayed activity in the cervical region as well. At a propagation velocity of 2 cm/second²⁻¹ and an estimated average distance of about 20 cm from a possible pacemaker location in the uterine fundus to the detecting electrodes at the cervix, the expected time delay is 10 seconds. In Fig. 1 the centre of the second and the third EMG burst is delayed to peak in IUP for more than 50 seconds. We can assume that the EMG activity registered in the cervix at this stage of labour has a source different from and independent of that in the uterine corpus. Also, the long delay excludes the possibility that EMG signals registered at the cervix have their origin in the fundus and are transmitted through the electrically conductive tissue to the location of detection.

Pajntar and Verdenik²⁰ demonstrated that average U_{RMS} values of EMG taken from the cervix in the latent phase were significantly higher in women with an unripe cervix (low Bishop scores) than in those with a ripe cervix (high Bishop scores) throughout the observed period close to amniotomy in an oxytocin induced labour. They found a significant

positive correlation between EMG U_{RMS} and the duration of the latent phase of labour. In our case, U_{RMS} values (Fig. 1 - trace 3) are high during EMG bursts occurring both synchronously and asynchronously with uterine fundus contractions. Asynchronous EMG bursts having high U_{RMS} indicate independent cervical smooth muscle activity and advocate for a relatively unripe cervix.

A closer look into the frequency content of the registered EMG could further characterise the EMG activity in the cervix. Median frequency value alternates with U_{RMS} value (see temporal presentation in Fig. 1 - trace 3 and trace 4). When median frequency is high, U_{RMS} is low. In unripe cervixes, median frequency is high (1.1 Hz-1.4 Hz) when only the permanent background EMG activity is present. The decrease in median frequency to 0.25 Hz-0.4 Hz could always be related to an EMG burst appearance.

The results of EMG spectral analyses presented as power spectrum are in agreement with the results of authors analysing the EMG of the smooth muscles of the uterine CORPUS²⁵ and those analysing the EMG derived from the cervix^{18,36,38}. The EMG signals of the cervical smooth muscles, as recorded by our group, lie within the frequency band width defined by Devedeaux *et al.*²⁶ as 'fast wave band'.

Power spectrum of the cervical EMG activity may have one or two separated frequency bands^{12,18,36,38}. In Fig. 2 the results of spectral analysis of the EMG signal presented in Fig. 1 - trace 2 are given. The lower part with frequency components up to 0.6 Hz reflects the frequency content of EMG bursts, whereas the higher part with frequencies ranging from 1.0 Hz to 1.3 Hz corresponds to the permanent background EMG activity. A clear gap between those bands advocates for two different contraction mechanisms and/or a

different origin of the EMG activity in the cervix.

CONCLUSIONS

During labour EMG bursts asynchronous with uterine contractions can be generated by smooth muscles of a relatively unripe cervix. EMG bursts with low median frequency and high signal amplitude (U_{RMS}) appear independent of uterine contractions or are delayed to the intrauterine peak value. Independent asynchronous EMG bursts advocate for active smooth muscle contraction in the relatively unripe cervix during labour. The delayed EMG bursts may be an active response to the passive stretching of the cervical smooth muscle tissue during a uterine corpus contraction. The observations are in agreement with the findings of Olah, who mechanically registered a cervical constriction as a consequence of prior dilatation during contraction of the uterine corpus.

The frequency content of the registered EMG signals is divided into two separate frequency bands where the lower band belongs to the EMG bursts and the higher to the EMG background activity. A clear gap between these bands advocates for two different contraction mechanisms of the cervical smooth muscle tissue and/or a different origin of the EMG activity in the cervix.

Acknowledgements

The research was supported by the Ministry of Science and Technology of Republic of Slovenia. The authors would like to thank Mr B. Leskošek for his assistance in signal processing.

References

1. Pajntar M, Roškar E, Rudel D. EMG of uterine corpus and cervix during labour. In: Proceedings of the *1st International Symposium on the Pregnant Uterus*. Debrecen, 1983; 66.
2. Ulmsten U, Ekland K. The forces of labor: uterine contractions and the resistance of the cervix. In: Pitkin RM, Scott JR, Ulmsten U, Ueland K, editors. *Clinical Obstetrics and Gynecology*. Philadelphia: Harper & Raw, 1983; 1-3.
3. Huszar GB, Walsh MP. Relationship between myometrial and cervical function in pregnancy and labor. *Selil in Perintol* 1991; 2: 97-117.
4. Olah KSJ, Gee H. The prevention of preterm delivery--can we afford to continue to ignore the cervix? *Br J Obstet Gynaecol* 1992; 99: 278-280.
5. Olah KSJ, Gee H. The active mismanagement of labour. *Br J Obstet Gynaecol* 1996; 103: 729-731.
6. Olah KS, Gee H, Brown JS. Cervical contractions: the response of the cervix to oxytocic stimulation in the latent phase of labour. *Br J Obstet Gynaecol* 1993; 100: 635-640.
7. Pajntar M. The smooth muscles of the cervix in labour. *Eur J Obstet Gynecol Reprod Biol* 1994; 55: 9-12.
8. Danforth DN. Distribution and functional significance of the cervical musculature. *Am J Obstet Gynecol* 1954; 68: 1261. Danforth DN. The morphology of human cervix. In: Pitkin RM, Scott JR, Ulmsten U, Ueland K, editors. *Clinical Obstetrics and Gynecology*. Philadelphia: Harper & Raw. 1983: 7-13.
9. Danforth DN. The morphology of human cervix. In: Pitkin RM, Scott JR, Ulmsten U, Ueland K, editors. *Clinical Obstetrics and Gynecology*. Philadelphia: Harper & Raw. 1983: 7-13.
10. Leppert PC. Anatomy and physiology of cervical ripening. *Clin Obstet Gynecol* 1995; 38: 267-279.
11. Stys S, Clewell WH, Mechia G. Changes in cervical compliance at parturition independent of uterine activity. *Am J Obstet Gynecol* 1978; 130: 414-418.
12. Pajntar M, Roškar E, Rudel D. Electromyographic observations on the human cervix during labor. *Am J Obstet Gynecol* 1987; 156: 691-697.
13. Gee H. The cervix in labour. *Contemp Rev Obstet Gynaecol* 1994; 6: 84-88.
14. Olah KS, Gee H, Brown JS. The effect of cervical contractions on the generation of intrauterine pressure during the latent phase of labour. *Br J Obstet Gynaecol* 1994; 101: 341-343.
15. Olah KSJ, Neilson JP. Failure to progress in the management of labour. *Br J Obstet Gynaecol* 1994; 101: 1-3.
16. Serr DM, Porath-Furedi A, Rabau E, Zakunt H, Mannor S. Recording of electrical activity from the human cervix. *J OIJ (et Gynaecol Br OJ) 1968; 75: 360-363.*
17. Jarakov L, Nedeltschewa E. Elektrohysterographische untersuchungen bei nomlaler wehentatigkeit. *Zbl Gynik* 1973; 95: 876-885.
18. Roškar E. Microcomputer based urodynamic and electromyographic techniques for urogenital tract diagnosing. *PhD Thesis, University of Ljubljana, Faculty of Electrical Engineering, 1984.*
19. Olah KS. Changes in cervical electromyographic activity and their correlation with the cervical response to myometrial activity during labour. *Eur J Obstet Gynaecol Reprod Biol* 1997; 57: 157-159.
20. Pajntar M, Verdenik I. Electromyographic activity in cervixes with very low Bishop score during

- labor. *Int J Gynecol Obs(et* 1995; 49: 277-281.
21. Pajntar M, Verdenik I, Pusenjak S, Rudel D, Leskosek B. Activity of smooth muscles in human cervix and uterus. *Eur J Obs(et Gynecol Reprod Biol* 1998. In press.
 22. Pajntar M, Rudel D. Changes in electromyographic activity of the cervix after stimulation of labour with oxytocin. *Gynecol Obsrser !III'es(* 1991; 31: 204-207.
 23. Pajntar M, Rudel D. Effect of spasmolytic Dolantin on the electromyographic activity of the cervix during labour. *Clin E.\P Obst Gyn* 1992; 19: 9-14.
 24. Wolfs G, Van Leeuwen M. Electromyographic observations of the human uterus during labour. *Acta Obstet Gynecol Scand* 1979; 90 (Suppl): 1-62.
 25. Marque C, Duchene J, Leclercq S, Panczer G, Chaumont J. Uterine EHG processing for obstetrical monitoring. *IEEE Trans Biomed Eng* 1986; 33: 1182-1187.
 26. Devedeux D, Marque C, Mansour S, Germain G, Duchene J. Uterine electromyography: a critical review. *Am JObstet Gynecol* 1993; 168: 1636-1653.
 27. Duchene J, Devedeux D, Mansour S, Marque C. Analyzing uterine EMG: tracking instantaneous burst frequency. *IEEE Eng Med Biol* 1995; 3: 125-132.
 28. Kao CY. Electrophysiological properties of uterine smooth muscle. In: Wynn RM, Jollie WP, editors. *Biology of the Uterus*, New York: Plenum Medical Book Co., 1989; 403--454.
 29. Bishop EH. Pelvic scoring for elective induction. *Obstet Gynecol* 1964; 24: 226.
 30. Rudel D. Cervical Electromyographic Activity as an Indicator of Cervical Ripeness, *PhD Thesis [in Slovene], University of Ljubljana, Faculty of Medicine, 1996.*
 31. Kawarabayashi T, Marshall JM. Factors influencing circular muscle activity in the pregnant rat uterus. *Biol Reprod* 1981; 24: 373-379.
 32. Bolzer E. The response of smooth muscle to stretch. *Am J Physiol* 1947; 149: 299-301.
 33. Burnstock G, Holman ME, Prosser CL. Electrophysiology of smooth muscle. *Physiol Rev* 1963; 43: 482-527.
 34. Csapo AI. The uterus: a model for medical considerations. In: Laki K, editor. *Contractile Proteins and MI/sele*. New York: Marcel Dekker, 1971: 413--482.
 35. Gondry J, Marque C, Duchene J, Cabrol D. Electrohysterography during pregnancy: Preliminary report. *Biomed IIIStYl/melll Teclmol* 1993; 27: 318-324.
 36. Roškar E, Pajntar M, Rudel D. Signal processing of human parturient uterine corpus and cervix electromyography—a new approach to quantified clinical monitoring of labour. *Med Biol Eng Comput* 1985; 23 (Suppl2): 940-941.
 37. Pajntar M, Roškar E, Rudel D. Longitudinally and circularly measured EMG activity in human cervix during labour. *Acta Physiol Hung* 1988; 71: 497-502.
 38. Pajntar M, Verdenik I, Rudel D, Valentincic B. Registration and analysis of cervical EMG during labour. In: Proceedings of the IV International Symposium on Biomedical Engineering. International Federation of Biological Engineering. Peniscola, Spain 1991: 97-98.